

# Retrospective Analysis of the Farrior Technique for Otoplasty

Scott A. Scharer, MD; Edward H. Farrior, MD; Richard T. Farrior, MD

**Objective:** To evaluate clinical outcomes and patient satisfaction following otoplasty for surgical correction of protruding or prominent ears using the Farrior technique.

**Methods:** This was a retrospective study of patients undergoing cosmetic otoplasty with the Farrior method at a private facial plastic surgery practice in Tampa, Fla. The study population comprised 75 subjects desiring operative correction of auricular deformities by one of the authors (E.H.F.) over the past 15 years. The subjects (40 male and 35 female) ranged in age from 5 to 68 years, with a mean age of 23.9 years. Clinical follow-up ranged from 1 day to 7 years 2 months, with a mean duration of 1 year 5 days. The Farrior otoplasty is a graduated technique that combines elements of cartilage sculpting, suturing, and conchal setback procedures, and stresses a patient-specific, anatomy-directed approach. This method was first introduced in the literature in 1959 by the senior author (R.T.F.) and is continued to the present day by his son (E.H.F.). Main outcome measures included satisfactory correction of auricular deformity, incidence of postoperative complications, and degree of patient satisfaction with the procedure. These outcomes were compared with that of other otoplasty techniques and long-term studies in the literature.

**Results:** Of the 75 patients who underwent otoplasty via the Farrior technique over the last 15 years, bilateral otoplasties were performed in 69 (92%). Of the cases, 69 (92%) were primary procedures, with revision otoplasties con-

stituting 6 (8%) of the total. A combination of conchal cartilage reduction, cartilage scoring, and mattress suturing was the most frequently used maneuver (47 cases [63%]). Most cases were performed using local anesthesia (n=62 [83%]), with 18 (24%) of all cases having adjunctive procedures at the time of the otoplasty. No major complications (large hematoma, tissue necrosis, gross deformity, or significant wound infection) were documented. A total of 40 minor complications was observed in 29 patients, with suture extrusion and persistent auricular protrusion being the most common (occurring in 14 [19%] and 17 [23%] cases, respectively). Overall, 11 patients required revision surgery (9 for protrusion, 1 for hypertrophic scar, and 1 for cartilaginous callus). A majority of positive responses on an anonymous patient survey reflects a high degree of patient satisfaction with the procedure and results.

**Conclusions:** The Farrior otoplasty is a graduated technique that has met with clinical success over the years. It combines elements of cartilage shaping and suturing procedures and as such is susceptible to complications such as suture extrusion and auricular protrusion that are ascribed to similar otoplasty methods described in the literature. It allows for a directed approach to correct the causative anatomic defects, while maintaining a natural appearance. While further research and long-term analyses are encouraged, this technique remains a valuable component of a facial plastic surgeon's armamentarium.

*Arch Facial Plast Surg. 2007;9:167-173*

**E**ARS CONTRIBUTE SIGNIFICANTLY to the overall harmony of facial proportion. While not as prominent as the nose or eyes, irregularities in auricular size or form can distract observers and detract from an otherwise pleasant appearance. Since the 19th century, a myriad of operative procedures have been devised to help correct such cosmetic deformities. Beginning with Ely in 1881, many prominent surgeons have espoused techniques for cosmetic otoplasty, including large contributions from Luckett, Becker, Converse, Mustarde, and Furnas.<sup>1</sup>

In 1959, the senior author (R.T.F.) first published his method of otoplastic surgery for protruding ears.<sup>2</sup> While most techniques prior to this focused exclusively on

suture use or the sculpting of cartilage, the Farrior modification was a graduated approach that used components of both suture and sculpting techniques to create a natural postoperative appearance. This procedure was used faithfully over the years, and eventually adopted in practice by the originator's son (E.H.F.).

While several different otoplasty techniques have been studied in the literature with long-term reviews, the Farrior procedure had yet to be analyzed in a retrospective fashion. Such extended evaluations are critical to determine the true morbidity, benefit, and results derived from varying methods. We therefore performed a retrospective analysis of the Farrior technique to examine the patient population, aesthetic result, complica-

**Author Affiliations:**  
Jacksonville Otolaryngology & Facial Plastic Surgery, PA,  
Jacksonville, Fla (Dr Scharer).  
Dr E. H. Farrior is in private practice in Tampa, Fla. Dr R. T. Farrior is retired from practice.

**Table 1. Age Distribution of Study Population**

Age, y*	No. (%) of Patients
0-9	10 (13)
10-19	28 (37)
20-29	10 (13)
30-39	16 (21)
40-49	5 (7)
50-59	4 (5)
60-69	2 (3)

\*Mean age of 23.9 years, with a range of 5 to 68 years.

**Table 2. Otoplasty Techniques With Resultant Helical Projection**

Method of Otoplasty	No. of Patients	Measured Helical Projection
Conchal reduction, cartilage scoring, and mattress sutures	47	1.64 cm
Conchal setback with mattress sutures	12	1.63 cm
Cartilage scoring and mattress sutures	10	1.68 cm
Superior helical rim grafting with cartilage suturing	4	Not available
Different techniques used on each side	2	Not available

tion rate, and degree of patient satisfaction over an extended period. These data were then compared with published outcomes with other types of otoplasty.

## METHODS

A retrospective study was performed within the clinical database of the Farris Facial Plastic and Cosmetic Surgery Clinic, a private practice in Tampa, Fla. When the senior author retired in 2002, his years of medical records were either destroyed or placed in remote storage and were unobtainable for review purposes. This study therefore focused on patients of the senior author's son, who uses the identical otoplastic technique first proposed by his father. Patients undergoing aesthetic ear surgery within the last 15 years were identified, and their medical records were carefully analyzed. Persons with incomplete data or who underwent operative correction of congenital microtia or atresia deformities were excluded from the study. Individuals requiring cosmetic otoplasty for correction of large, protruding "lop" or "cup" ears were included in the investigation, and sufficient medical records were obtained for 75 individuals. Data were tabulated and analyzed in regard to age, sex, method of otoplasty, side involved, primary vs revision procedure, type of anesthesia, adjunctive procedures, duration of follow-up, and complications. An anonymous survey was also mailed to individuals who had undergone cosmetic otoplasty at the Farris Clinic, with 31 subjects responding. This survey contained 10 questions designed to ascertain the level of patient satisfaction with the entire otoplasty experience, from preoperative counseling through the actual procedure and postoperative results.

## RESULTS

A total of 75 subjects (40 male [53%] and 35 female [47%]) underwent elective surgical correction of pro-

**Table 3. Complications Following Otoplasty\***

Complication	No. of Occurrences	Mean Time of Occurrences	Outcome
<b>Major</b>			
Large hematoma, significant wound infection, gross deformity, tissue necrosis, keloid formation	0	...	...
<b>Minor</b>			
Persistent or recurrent ear protrusion	17	9.5 mo	Required revision otoplasty in 9 patients
Suture extrusion	14	15 mo	Removed in clinic or operating room
Hypertrophic scar	2	19 mo	1 Improved with intralesional corticosteroid injection; 1 required scar revision
Persistent irritation	2	2-32 mo	Resolved with conservative management
Suture granuloma	2	19 mo	Removed using local anesthesia
Small hematoma	1	1-3 d	Resolved with conservative management
Herpes zoster oticus	1	1-2 wk	Improved over 2-3 mo with corticosteroid and antiviral treatment
Small ulceration (anterior surface of antihelix)	1	2 mo	Required excision callus using local anesthesia at 6 mo

\*Total of 40 complications occurring in 29 patients.

truding ears over the last 15 years. The patients were aged 5 to 68 years, with a mean age of 23.9 years. **Table 1** stratifies the subjects by age. Bilateral otoplasties were performed in 69 patients (92%), with only 6 documented unilateral cases. Of the 75 cases, 69 (92%) were primary procedures, with revision otoplasties making up only 6 (8%) of the total. A combination of conchal cartilage reduction, cartilage scoring, and mattress suturing was the most frequently used method (47/75 [63%]), with a conchal setback and suturing technique used in 12 cases (16%), a cartilage scoring and suturing technique in 10 (13%), and unique modifications in approximately 11 patients (8%) (**Table 2**). Most cases were performed using local anesthesia (62/75 [83%]), with 18 of the 62 subjects requiring some form of additional oral or intravenous sedation. General anesthesia was used in 13 cases (17%), often in patients having additional procedures performed in the same setting. Such conjunctive procedures included septoplasty, rhinoplasty, blepharoplasty, chin revision, face-lift, endoscopic brow-lift, excision of skin lesions, and repair of torn ear lobes and occurred in 18 (24%) of the 75 cases. Cosmetic otoplasty was therefore the sole operative intervention in 57 patients (76%). The mean duration of follow-up was 1 year 5 days, with a range of 1 day to 7 years 2 months.

**Table 4. Patient Satisfaction Survey With Summary of Responses\***

Key	-2 Disagree Strongly	-1 Disagree Somewhat	0 Neutral	+1 Agree Somewhat	+2 Agree Strongly	Does Not Apply
1. Prior to my otoplasty, I was embarrassed/self-conscious about the size of my ears.	1/31 (3)	1/31 (3)	3/31 (10)	12/31 (39)	12/31 (39)	12/31 (6)
2. The procedure was thoroughly explained and the risks/benefits addressed prior to surgery.	0	0	0	4/31 (13)	27/31 (87)	0
3. Recovery from surgery was without any significant complications (bleeding, infection).	0	1/31 (3)	1/31 (3)	3/31 (10)	26/31 (84)	0
4. My otoplasty procedure achieved the stated goals of correcting prominent/protruding ears.	0	2/31 (6)	1/31 (3)	7/31 (23)	20/31 (65)	1/31 (3)
5. I am very happy with the shape and size of my ears following otoplasty.	0	2/31 (6)	0	11/31 (36)	18/31 (58)	0
6. The shape and size of my ears have not changed since the operation.	6/31 (19)	2/31 (6)	3/31 (10)	5/31 (16)	13/31 (42)	2/3 (6)
7. My otoplasty procedure has improved my self-esteem/self-confidence.	1/31 (3)	0	2/31 (6)	11/31 (36)	16/31 (52)	1/31 (3)
8. I believe my otoplasty has changed my life.	3/31 (10)	3/31 (10)	10/31 (32)	8/31 (26)	6/31 (19)	1/31 (3)
9. My otoplasty experience has left me with a favorable attitude toward cosmetic surgery.	0	0	2/30 (7)	14/30 (47)	14/30 (47)	0
10. My otoplasty experience was overall satisfactory, and I would recommend it to others.	0	0	1/31 (3)	6/31 (19)	24/31 (77)	0

\*Data are given as number/total number (percentage) of patients responding to the survey.

For this retrospective review, a major complication was defined as a large hematoma requiring evacuation, tissue necrosis, wound separation, gross cosmetic deformity, or a significant wound infection requiring intravenous antibiotics and/or incision and drainage. There were no major complications in this study. Minor complications included suture extrusion, hypertrophic scarring, irritation, hypesthesia, and persistent or recurrent protrusion of the auricle and are summarized in **Table 3**. A total of 40 minor complications was noted in 29 patients, with the 2 most common being suture extrusion and persistent auricular protrusion, which occurred in 14 (19%) and 17 (23%) of the 75 cases, respectively. On average, suture extrusion was noted to occur at 15 months (range, 2.5-36 months), with recurrent or persistent ear protrusion documented at 9.5 months (range, 3-18 months). Only 11 subjects required minor revision procedures, with the remaining cases improving with time and conservative management.

A total of 31 patient surveys were completed and mailed back to the Farnior Clinic. The anonymous questionnaire consisted of 10 statements to which each person had to rank his or her level of agreement. The results are given in **Table 4**, with overall positive feedback being observed.

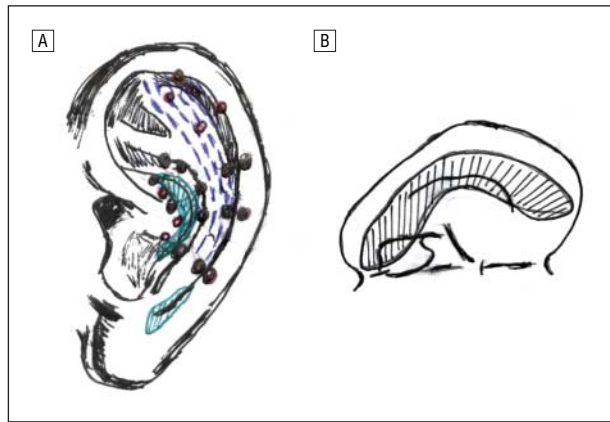
#### COMMENT

It is widely believed that the auricle is derived from the first 2 branchial arches during weeks 6 to 20 of gestation. The hillocks are fused by week 12, and by week 20, the auricle has reached its final shape but not size.<sup>3</sup> The ear continues to enlarge the first few years of life, and by age 3 years, an estimated 85% of the total growth has taken place.<sup>4</sup> By age 8 years, it is generally accepted that the ear has reached adult size.<sup>5</sup> Cephalometric studies, along with general societal and artistic consensus, have helped to establish "normal" pro-

portions for auricular anatomy. The upper limit of the ear should fall at eyebrow level, with the most inferior component in line with the nasal ala. The width should be about 60% of the ear length, with the vertical axis rotated roughly 15° posteriorly.<sup>6</sup> The auriculomastoid angle should approximate 20°, with the upper helical rim projecting 15 to 20 mm above the temporal bone.<sup>6</sup> Each auricle should consist of clearly defined anatomic components, including the tragus, antitragus, conchal bowl, lobule, superior and inferior crura of the antihelix, scaphoid fossa, and helix. Ideally, the antihelix should be most narrow and prominent inferiorly and gradually widen with lessening convexity as it blends superiorly with the crural junction. Likewise, the scaphoid fossa is deepest inferiorly and becomes shallower superiorly. The superior crus smoothly merges with both the scaphoid and triangular fossae, while the inferior crus has a sharper angulation.<sup>7</sup>

The anatomical basis for the auricular deformities observed in prominent, protruding, or lop ears can usually be attributed to a weak antihelical fold, a deep conchal bowl, or a combination of the two. While some of the earliest otoplasty techniques focused on reducing the distance between the auricle and scalp by excising soft tissue,<sup>1</sup> Lockett<sup>8</sup> is believed to have first recognized the importance of an absent or weak antihelix in the formation of the deformity. Later methods thus tended to focus on reestablishing an antihelical fold through suturing or cartilage-scoring procedures.

The most widely used suture technique was developed by Mustarde<sup>9</sup> in the early 1960s. A postauricular approach is used to achieve adequate exposure of the cartilaginous framework just above the posterior perichondrium. Next, 3 to 4 horizontal mattress sutures are placed at specific locations to recreate the antihelix.<sup>1</sup> From the posterior surface, each stitch should pass through the cartilage and anterior perichondrium, avoiding the anterior der-



**Figure 1.** Diagram of maneuvers commonly used in the Farrior otoplasty. A, Placement of mattress sutures and scoring incisions along the posterior surface, seen from the anterior view. Note the elliptical excision of lateral conchal cartilage along the conchal rim and trimming of cauda helicis inferiorly. No incisions through cartilage are made in the region of the superior crus. B, "Elliptical dumbbell" excision of skin seen from the posterior view.

mal and epidermal layer. Precise suture location is paramount to achieve a permanent, natural result without risk of extrusion, buckling, or auricular reprotrusion. Bull and Mustarde<sup>10</sup> recommended outer cartilage bites of 1 cm, with each being 2 mm apart, and a 16-mm separation between outer and inner cartilage bites. While some authors advocate using a Mersilene suture for this technique,<sup>1</sup> Bull and Mustarde preferred natural white silk material that could be cut close to the knot.<sup>11</sup> When used properly, the Mustarde suture technique can be a reliable method in properly selected patients. In a review of his 25-year experience with the procedure, Bull<sup>11</sup> concluded that it "continues to give good results," with a low incidence of suture extrusion. Despite meticulous technique, Bull<sup>11</sup> still found recurrence of the auricular deformity in approximately 7% of patients. In those less experienced with the method, improper suture placement can lead to an even higher incidence of reprotrusion. Especially in patients with strong, thick cartilage, many surgeons have realized that cartilage-weakening procedures would have to be added to break the cartilage's spring and inherent memory and help achieve good long-term results.<sup>1</sup>

Cartilage sculpting procedures attempt to contour the auricular cartilage with incisions, scoring, and/or abrading techniques in the absence of sutures. The selective weakening of cartilage to achieve a desired effect developed largely from research on rib grafts by Gibson and Davis,<sup>12</sup> who found bowing of cartilage to be influenced by the location of scoring and/or intact perichondrium.

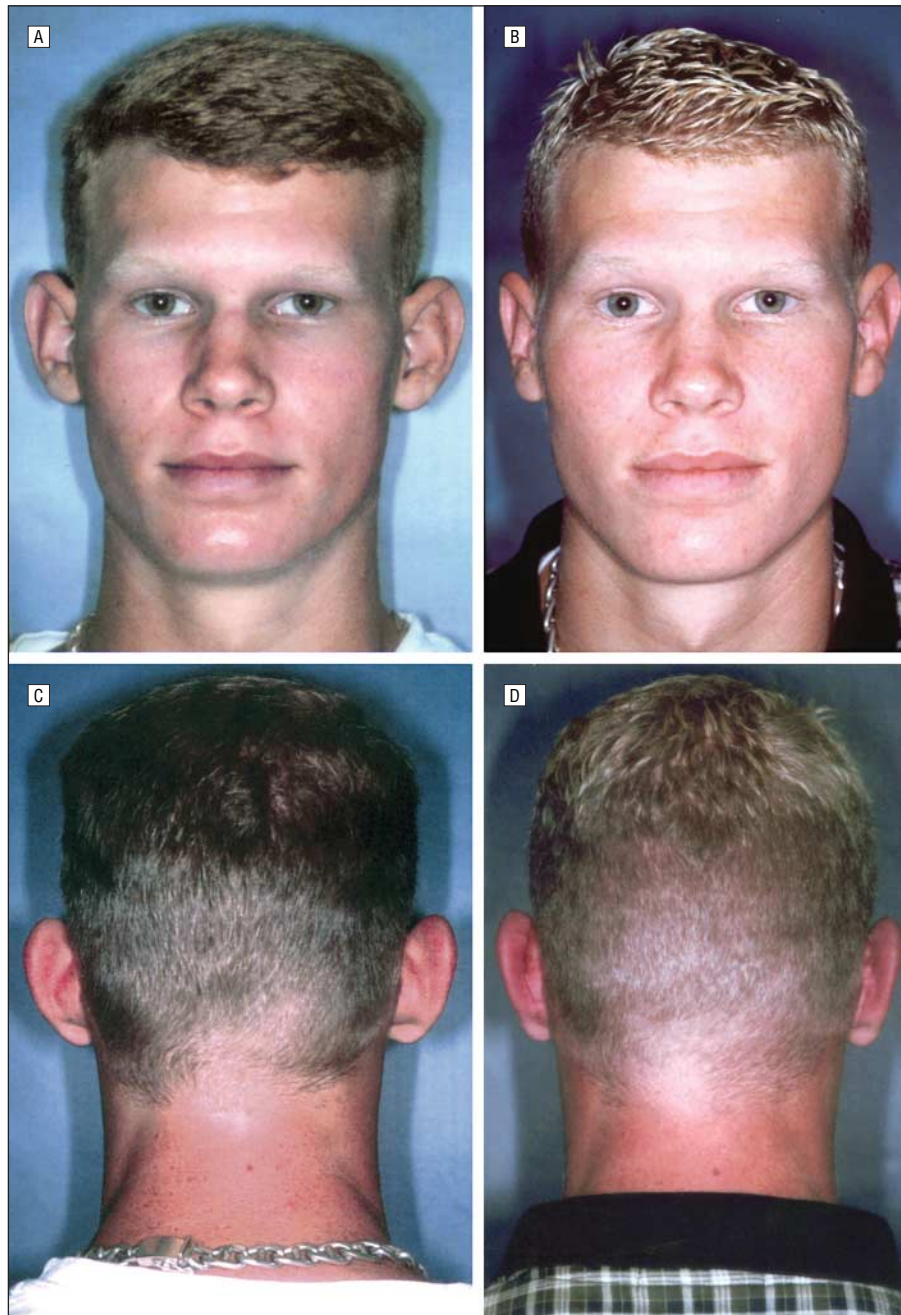
The last major type of otoplasty harkens back to the original attempts at correction of protruding ears by excision of intervening soft tissue and retrodisplacement of the ears. The conchal setback technique was described by Furnas<sup>13</sup> in the late 1960s and involves the use of permanent sutures to narrow a large space between the concha and mastoid process. As this method does not address the antihelix, it was advocated by Furnas<sup>13(p189)</sup> "when excessive cupping of the concha is the only cause for prominence of an ear." Small ellipses of skin are removed from the postauricular surface and mastoid, and

3 or more permanent sutures are then passed between the conchal cartilage and deep mastoid fascia and periosteum. The ear is subsequently drawn posteriorly and medially by tightening of the stitches. In the instance of an excessively deep conchal bowl, an elliptical piece of lateral conchal cartilage may be excised prior to suture placement.<sup>1</sup> The conchal setback is an effective maneuver in the appropriate patient, but proper suture location is imperative or impingement of the external auditory canal may result.<sup>13</sup>

The Farrior otoplasty combines elements of the cartilage sculpting, suturing, and conchal setback techniques in a method that stresses anatomical evaluation and a graduated approach.<sup>14</sup> The prominent ear is carefully analyzed preoperatively and intraoperatively, and only the maneuvers necessary to achieve the desired result are performed.

In the Farrior technique, the maneuvers that will be used are based on several factors. One must consider the thickness and resilience of the auricular cartilage, the depth and degree of cupping of the conchal cavity, the existing convexity of the antihelix and concavity of the scaphoid fossa, the development of the helical rim, the pillar effect of the inferior crus, and the possibility of a resistant superior quarter of the ear.<sup>7</sup> Each otoplastic procedure is thus tailored to the aberrant anatomy, and the simplest methods are used first to try and achieve the desired contour.<sup>7</sup> If a weak or absent antihelical fold is the problem and the patient's cartilage is thin and compliant (as often encountered in a child), then mattress sutures alone may be successful. Oftentimes, scoring of the cartilage to break the resilient spring is necessary in conjunction with suturing. If a deep conchal bowl is the lone culprit, then a conchal reduction with elliptical excision of a cartilage along the conchal rim, plus or minus conchal-mastoidal sutures, may be all that is required. As mentioned previously, it is often a combination of antihelical and conchal deformities that result in protruding ears, and several maneuvers are needed. Most frequently, elements of conchal reduction, cartilage scoring, and suturing are all used from a postauricular approach. In addition, trimming of the cauda helicis and excision of an "elliptical dumbbell" segment of postauricular skin are often necessary. **Figure 1** diagrams these commonly used maneuvers, the combination of which achieves adequate correction in most cases.<sup>7</sup> **Figure 2** demonstrates typical preoperative and postoperative views of a patient undergoing otoplasty using this standard procedure. When the ear is very resilient, particularly the superior third of the auricle, more advanced techniques may be needed. These include extension of the scaphoid incision superiorly or the conchal rim incision into the inferior crus when the crural junction is particularly stubborn, placement of horizontal mattress sutures parallel to the superior crus in a resistant ear, or the sectioning or removal of a portion of the anterior inferior crus when the structure creates a strong pillar effect.<sup>7,14</sup>

This procedure has been a reliable technique for the Farriors and other surgeons over the last several decades, but, to our knowledge, this is the first retrospective analysis that has been performed. In reviewing the data collected from 75 patients, many interesting trends were re-

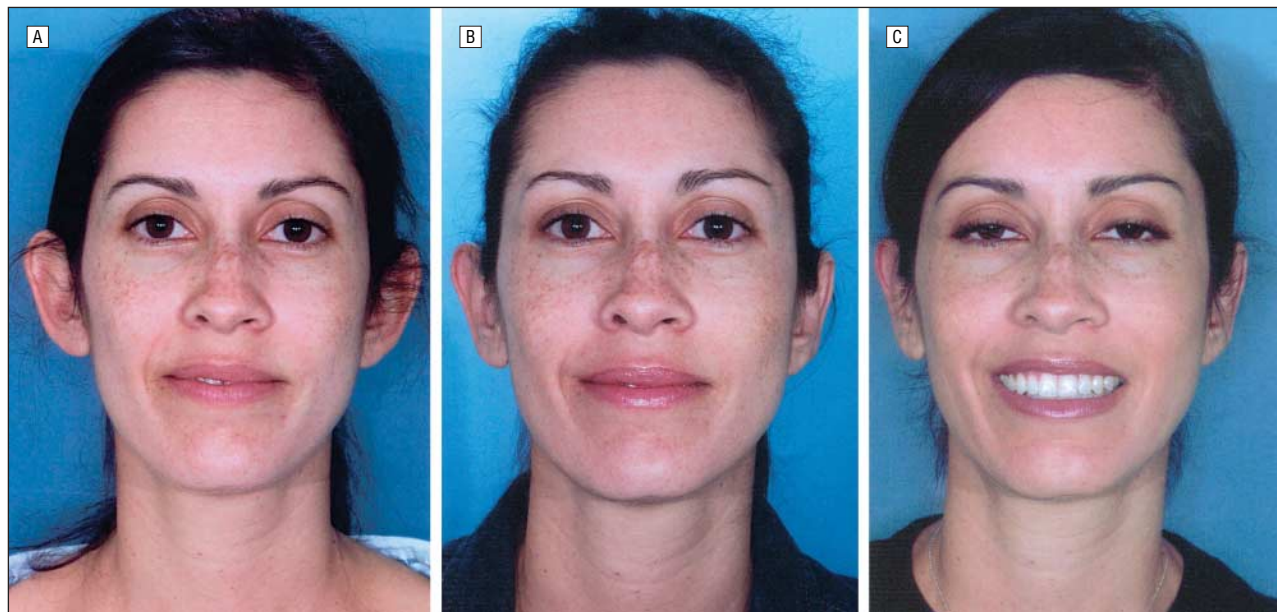


**Figure 2.** Preoperative and postoperative photographs of a male patient undergoing bilateral otoplasty via the Farrior technique. A, Preoperative frontal view; B, postoperative frontal view; C, preoperative rear view; and D, postoperative rear view.

vealed. The fairly equal amount of male and female subjects in this analysis was anticipated, as there is no sex predilection for protruding ears to our knowledge. A mean follow-up duration of just over 1 year is also not unusual, since it is the standard practice of the surgeon in this study (E.H.F.) to release patients from scheduled clinic visits after the annual follow-up. Patients are instructed to return as needed, and it is reasonable to assume that in a private facial plastic surgery practice, the clientele will likely return if a problem arises. The various maneuvers used in the otoplasties (as given in Table 2) serve to underscore the patient-specific, problem-directed approach that is paramount in the Farrior technique. The deformity dictates the maneuvers to be used, with a fairly equal mean projection distance being achieved regardless of the technique

(with 1.5-2.0 cm being the target distance between the helix and mastoid).

The mean age of the patients at the time of otoplasty was higher than expected at 23.9 years. As previously mentioned, the majority of auricular growth has taken place by age 8 years.<sup>15</sup> The literature recommends elective correction of protruding ears starting at approximately age 5 years, when adequate ear development has taken place and the patient is beginning to be subjected to psychosocial stressors such as teasing.<sup>1,7,15</sup> Table 1 shows that the greatest percentage of patients were fairly young, with 37% aged between 10 and 19 years. The next most represented group, however, was aged between 30 and 39 years. The reason for this age distribution is unclear, but a greater than expected representation by patients in their



**Figure 3.** Female patient who required revision otoplasty on the right for protrusion of the superior helix. A, Preoperative frontal view; B, frontal view following the first procedure (note some persistent protrusion of the right superior helix); and C, frontal view following right revision otoplasty (note overall symmetry and natural look of ears).

third or fourth decade may reflect the national trend toward more cosmetic procedures being performed among adults in general. Many older individuals may wish to finally have their ears addressed at the time of other cosmetic procedures. This is supported by the fact that of the 75 otoplasties in this study, 18 (24%) were performed in conjunction with other operations.

Another surprising finding was the apparent minor complication rate in the study. While no major complications occurred during the 15-year period, the data indicate that a high number of minor complications took place. A total of 40 minor complications was documented in 29 patients, inferring that a minor complication affected 39% of the subjects. The literature supports a much lower mean complication rate in otoplasty, regardless of the technique. After reviewing 562 cases, one physician concluded that an “inexperienced” otoplasty surgeon had a mean complication rate of 20%, while the rate for an “experienced” surgeon was 9%.<sup>16</sup> The surgeon in this retrospective study was undoubtedly well versed and proficient in the procedure. In addition, the Farrow technique has been used for decades and found to give consistent, reliable, aesthetically pleasing results; otherwise, modifications would have been made. Therefore, one must question why the minor complication rate appears to be so high. Scrutiny of the events categorized as complications may shed some light on the calculations. Suture extrusion, persistent or recurrent auricular protrusion, hypertrophic scarring, persistent irritation, suture granuloma, “small” hematomas not requiring intervention, and small ulcerations all fell under the category of minor complications in this study. Certainly, excessive scarring, ulcerations, and blood collections can be considered complications, and the overall occurrence of these was low at 5% (4/75 patients). Persistent irritation was documented in 2 patients (3%) over the postoperative course. This finding can be somewhat subjective, however, and may vary depending on factors such

as patient expectation, pain threshold, and activity level. In their review of otoplasty complications, Weerda and Siegert<sup>17</sup> recognize that paresthesias, hypersensitivity, and pain can occur as either early or late complications and typically lessen over time. Suture extrusion was one of the most frequently observed events and, together with suture granuloma, made up 40% of all complications (16/40). This complication is frequently noted in the otoplasty literature and can often be attributed to improper suture placement or infection. Some authors debate the tendency of certain stitch material to extrude or irritate the overlying skin. As previously noted, Bull and Mustarde preferred natural silk,<sup>11</sup> while other authors advocate Mersilene suture or vicryl.<sup>1,17</sup> A 4-0 Mersilene suture was used selectively in this study and has been very reliable and inert in the clinical setting. If suture extrusion occurs in the immediate postoperative period, then removal of the stitch may predispose to weakening of the cartilage and reprotrusion of the auricle. The mean time of suture extrusion in this study was 15 months, and most of the stitches were removed in the clinic without difficulty and without contributing to recurrence of deformity.

Persistent auricular protrusion, particularly of the superior portion of the ear, was the most commonly observed minor complication. These were noted at a mean 9.5 months after surgery and represented 43% of the total complications (17/40). This finding is frequently recognized in the literature, with some authors estimating it to occur at a rate of 3% to 8%.<sup>16,17</sup> In fact, others have gone as far as considering it a common occurrence following otoplasty and is to be expected in many instances. Stal and Spira<sup>18</sup> found some amount of reprotrusion in every patient, particularly at the superior pole. Messner and Crysdale<sup>19</sup> report that an average of 58% of the operative medialization was lost postoperatively at the superior rim. They conclude that “with time, a substantial loss of correction can be expected in most (but not all) patients who un-

dergo otoplasty, particularly at the upper pole.”<sup>19(p773)</sup> Despite the number of persistent or recurrent protrusions in the present study, only 9 patients ultimately required a revision procedure (**Figure 3**), and most people seemed satisfied with their otoplasty experience. This can be gleaned from the anonymous survey results, as given in Table 4. The responses showed that the majority of people were happy with the size and shape of their ears following the operation (question 5) and believed that the procedure had achieved the stated goals (question 4). The only question with a substantial fraction of negative responses was question 6, and this may be secondary to poor wording. “The shape/size of my ears have not changed since the operation” may have been misinterpreted by some to imply that the shape or size of the ears were not affected by the surgery, not that changes took place following the surgery, which was the original intent of the question. Given the polarized results for that question and in light of the overwhelmingly positive responses for the remainder of the inquiries concerning outcome and patient satisfaction, confusion on behalf of the reader is a definite possibility. Other survey questions will have to be worded more carefully in the future.

## CONCLUSIONS

The correction of prominent and protruding ears can be a source of great satisfaction for both the surgeon and patient. For over a century, physicians have sought to change the size or shape of disproportioned auricles through various techniques. The most popular and successful procedures typically involve permanent suture placement, cartilage sculpting, or a combination of the two. In 1959, the senior author proposed a graduated technique of otoplasty that stressed a patient-specific, anatomy-directed approach. This method has been used for over 4 decades and has met with great clinical success. A retrospective review of 75 patients over the last 15 years has been presented. Many aspects of the Farrow technique have been discussed, including observed complications and subject satisfaction following the operation. While patients and surgeons continue to be pleased overall with the procedure, the incidence of postoperative complications encountered with this method, and in the literature in general, highlight the difficulty inherent in otoplasty. Further research and outcomes analyses are critical to ensure that the procedure continues to evolve as needed and that patients are offered the safest, most effective techniques available.

Accepted for Publication: January 6, 2007.

**Correspondence:** Scott A. Scharer, MD, Jacksonville Otolaryngology & Facial Plastic Surgery, PA, 836 Prudential Dr, Suite 807, Jacksonville, FL 32207-8335 (sscharer@comcast.net).

**Author Contributions:** *Study concept and design:* Scharer. *Acquisition of data:* Scharer. *Analysis and interpretation of data:* Scharer. *Drafting of the manuscript:* Scharer. *Critical revision of the manuscript for important intellectual content:* E. H. Farrow. *Statistical analysis:* Scharer. *Administrative, technical, and material support:* E. H. Farrow and R. T. Farrow. *Study supervision:* E. H. Farrow.

**Financial Disclosure:** None reported.

**Acknowledgment:** We thank the staff of the Farrow Facial Plastic and Cosmetic Surgery Clinic and Erin Scharer, BSN, for their assistance in preparation of this manuscript.

## REFERENCES

1. Nachlas NE. Otoplasty. In: Papel ID, ed. *Facial Plastic and Reconstructive Surgery*. 2nd ed. New York, NY: Thieme Medical Publishers, Inc; 2002:309-321.
2. Farrow RT. A method of otoplasty. *Arch Otolaryngol*. 1959;69:26-34.
3. Lee KJ. Anatomy of the ear. In: Lee KJ, ed. *Essential Otolaryngology*. 8th ed. New York, NY: McGraw-Hill; 2003:1-23.
4. Adamson JE, Horton CE, Crawford HH. The growth pattern of the external ear. *Plast Reconstr Surg*. 1965;36:466-470.
5. Stark RB, Saunders DE. Natural appearance restored to the unduly prominent ear. *Br J Plast Surg*. 1962;15:385-397.
6. Ridley MB, VanHook SM. Aesthetic facial proportions. In: Papel ID, ed. *Facial Plastic and Reconstructive Surgery*. 2nd ed. New York, NY: Thieme Medical Publishers, Inc; 2002:96-109.
7. Farrow RT. Otoplasty: surgery for protruding ears. In: *Otolaryngology*. Vol 3. Hagerstown, Md: Harper & Row Publishers, Inc; 1974:1-23.
8. Lockett W. A new operation for prominent ears based on the anatomy of the deformity. *Surg Gynecol Obstet*. 1910;10:635-637.
9. Mustarde JC. Correction of prominent ears using simple mattress sutures. *Br J Plast Surg*. 1963;16:170-178.
10. Bull TR, Mustarde JC. Mustarde technique in otoplasty. *Facial Plast Surg*. 1985; 2:101-107.
11. Bull TR. Otoplasty: Mustarde technique. *Facial Plast Surg*. 1994;10:267-276.
12. Gibson T, Davis WB. The distortion of autogenous cartilage grafts: its cause and prevention. *Br J Plast Surg*. 1958;10:257-274.
13. Furnas DW. Correction of prominent ears by concha-mastoid sutures. *Plast Reconstr Surg*. 1968;42:189-193.
14. Farrow RT. Otoplasty for children. *Otolaryngol Clin North Am*. 1970;3:365-374.
15. Kotler HS, Robertson K, Tardy ME. Pre- and postoperative management in otoplasty. *Facial Plast Surg*. 1994;10:244-254.
16. Calder JC. Morbidity of otoplasty: a review of 562 consecutive cases. *Br J Plast Surg*. 1994;47:170-174.
17. Weerda H, Siegert R. Complications in otoplastic surgery and their treatment. *Facial Plast Surg*. 1994;10:287-297.
18. Stal S, Spira M. Long-term results in otoplasty. *Facial Plast Surg*. 1985;2:153-165.
19. Messner AH, Crysdale WS. Otoplasty: clinical protocol and long-term results. *Arch Otolaryngol Head Neck Surg*. 1996;122:773-777.

## Announcement

Visit [www.archfacial.com](http://www.archfacial.com). As an individual subscriber you can send an e-mail to a friend. You may send an e-mail to a friend that includes a link to an article and a note if you wish. Links will go to free abstracts whenever possible.